

Keyhole Approach for Posterior Cervical Discectomy: Experience on 84 Patients

Author

Y. Ş. Çağlar¹, M. Bozkurt¹, G. Kahilogullari¹, H. Tuna¹, A. Bakir², F. Torun¹, H. C. Ugur¹

Affiliation

¹ Department of Neurosurgery, Ankara University, School of Medicine, Sıhhiye, Ankara, Turkey

² Department of Neurosurgery, Mevki Military Hospital, Ankara, Turkey

Key words

- Cervical radiculopathy
- disc herniation
- keyhole
- anatomy

Abstract

Anterior cervical discectomy with or without fusion has been commonly used for cervical disc disease since the description by Smith and Robinson in 1958. In this report, surgical technique, advantages, and disadvantages of the posterior approach, known as the posterior keyhole laminotomy-foraminotomy, are reviewed and motion versus fusion surgery discussed. Between 1996 and 2004, the keyhole laminotomy-foraminotomy was performed on 84 patients suffering from lateral cervical soft disc herniation or osteophytes. All the procedures were performed under the surgical microscope. A high-speed drill was used for drilling the bone. In 49 patients (58%), soft disc herniation was removed, while

in 35 patients (42%) there were osteophytes. Successful relief of radiculopathy symptoms was achieved in 80 patients (96%). In 4 patients the symptoms recurred. One patient (1.2%) developed kyphosis. The only complication observed intraoperatively was a partial root injury in one patient (1.2%). Mean hospitalization time was 48 hours. The posterior approach is particularly appropriate in patients whose root compression is located posterolaterally. Advantages of this surgery are minimal lamina resection, good visualization of the nerve root, postoperative early mobilization and minimal hospitalization. Microsurgery enables us to both preserve the motion of operated segment and avoid cervical instability.

Introduction

Radiculopathy or myelopathy caused by cervical disc disease has received considerable attention in the literature. Spurling and Scoville in 1944 and Frykholm in 1947 described the technique of posterolateral decompression. This approach has been less frequently used since the description of the anterior approach to the cervical nerve root by Smith and Robinson in 1958 [1–3]. The posterior approach is particularly appropriate for patients whose soft disc herniation originates from the posterolateral location, lying lateral to the cord and compressing the nerve root (● Fig. 1A). It is also appropriate for those with osteophytes originating from facet joint and arm symptoms more serious than neck symptoms that do not respond to the conservative treatment [4,5].

The aim of this study was to describe the surgical technique, advantages, and disadvantages of the posterior approach, called the posterior keyhole laminotomy-foraminotomy.

Patients and Methods

Between 1996 and 2004, the keyhole laminotomy-foraminotomy was performed on 84 patients suffering from lateral cervical soft disc herniation or osteophytes. The levels of the lesions are summarized in ● Table 1. All the procedures were performed under the surgical microscope. A high-speed drill was used for drilling the bone. Fifty-eight percent of the patients were male, and 42% were female. The mean age of the patients was 49 ± 8.3 years. The mean follow-up was 94 ± 8 months.

Surgical technique

Cardiopulmonary functions were evaluated carefully before the operation to decrease the venous pressure and avoid epidural bleeding during the operation. Antithrombotic drugs and anti-inflammatory drugs were stopped 3 days prior to the surgery. An arterial line, urethral catheter and triple lumen catheter were inserted for monitoring. Antiembolism socks were routinely applied,

Bibliography

DOI 10.1055/s-2007-970138
Minim Invas Neurosurg 2007;
50: 7–11

© Georg Thieme Verlag KG
Stuttgart · New York ·
ISSN 0946-7211

Correspondence

Y. Ş. Çağlar, MD
Professor of Neurosurgery
Department of Neurosurgery
Ankara University
İbni Sina Hospital
06100 Sıhhiye
Ankara
Turkey
Tel.: +90/532/232 72 40
sukrucaglar@yahoo.com

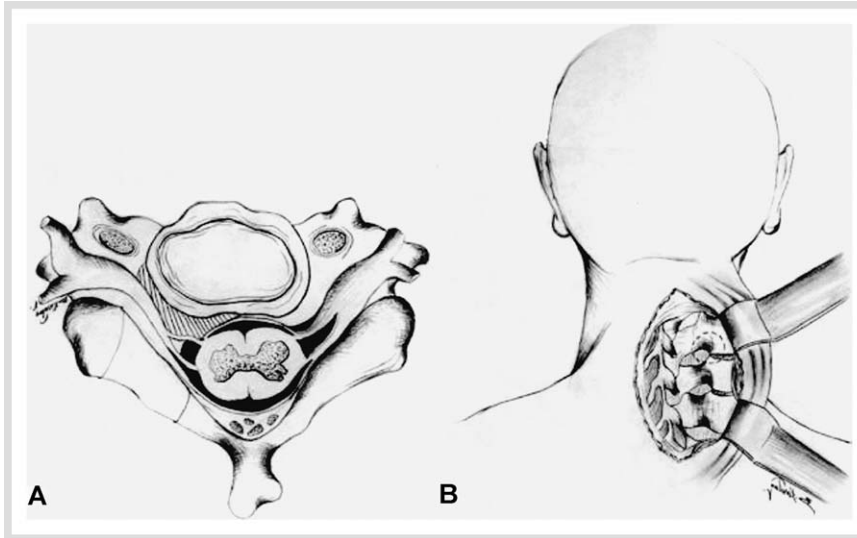


Fig. 1 A Illustration of a posterolaterally located soft disc herniation. B Illustration of the approach.

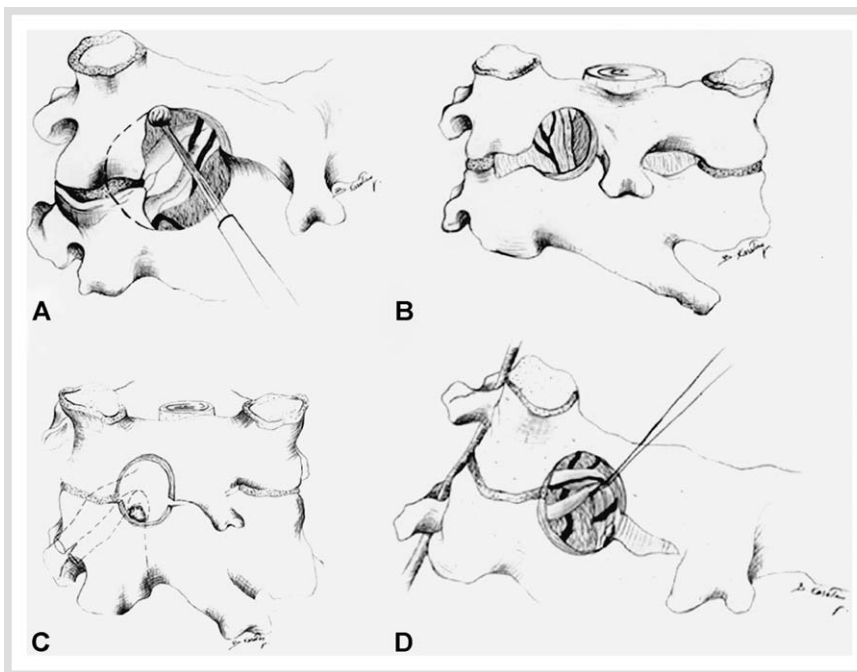


Fig. 2 A Illustration of drilling of the medial facet joint and lamina. B Illustration of the keyhole and ligamentum flavum. C Illustration of the nerve root, dural sheet and fragment. D Illustration of the rostrally retracted nerve root.

Table 1 The levels of the lesions

Level	Number of patients	Percentage (%)
C5-6	35	41
C6-7	44	52
C4-5	3	4
C5-6, 6-7	2	3

and the patients underwent general anesthesia. The sitting position was selected in all the applications to assure a decreased risk of venous bleeding and a straightforward visualization of the nerve root [5]. Although the incidence of air embolism during this procedure is very low, proper precautions were taken. Zeidman reported four cases of asymptomatic air embolism in his series of 172 patients [6]. A single dose intravenous antibiotic was administered in the operating room. If severe root retraction was anticipated during the surgery, intravenous corticosteroids were administered. The head was placed into a Mayfield type head-rest. After positioning, a lateral radiograph was obtained with a needle to confirm the incision level. After veri-

fication of the incision level, a midline incision of 3 cm was performed for a single level. The superficial fascia and nuchal ligament were also incised. Subperiosteal paraspinal muscle dissection was performed, and muscles were retracted lateral to the facet joint (● Fig. 1B). Thus, the interlaminar space was identified and soft tissues overlying this space were removed. To reconfirm the level, a lateral intraoperative radiograph was obtained. Spinous process, facet joint, and adjacent lamina were identified. At the junction of the medial facet joint and lamina, bone removal was performed with the help of a high-speed drill under the surgical microscope (● Fig. 2A). However, removing the facet joint by more than 50% percent is not recommended because of the risk of instability. The ligamentum flavum was identified and removed (● Fig. 2B). At this point nerve root, dural sheet, and fragment were observed (● Fig. 2C). The nerve root lies above the pedicle. The pedicle was identified and followed to the posterolateral margin of the vertebral body to gain an epidural plane, and the medial border of the pedicle was drilled. The nerve root was retracted rostrally because the herniated fragment is frequently located inferior to the nerve root

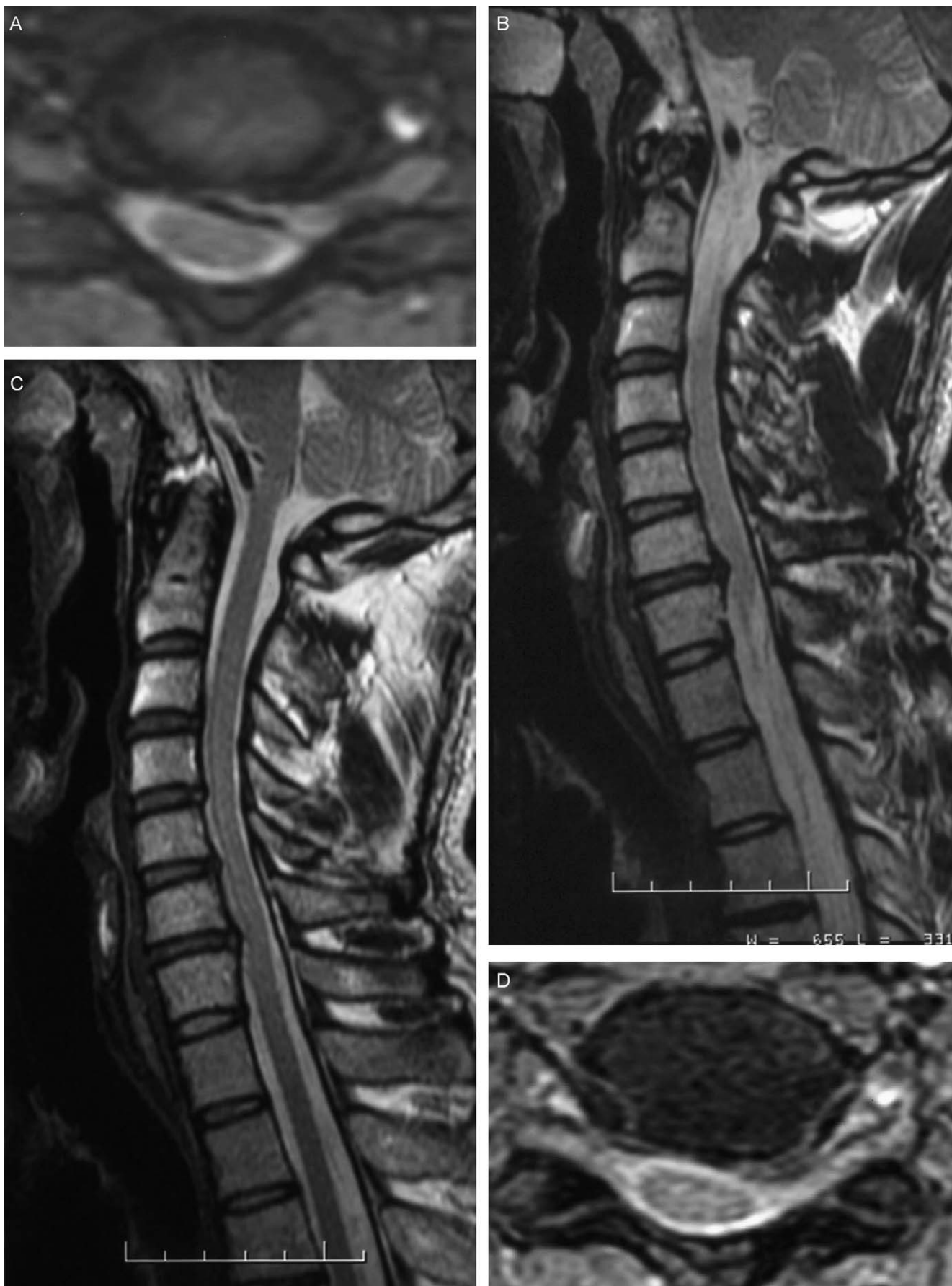

Fig. 3 A T₂-weighted cervical axial MRI showing soft disc herniation on the left side. B T₂-weighted cervical sagittal MRI showing soft disc herniation on the C5–C6 level. C T₂-weighted cervical axial MRI, the soft disc herniation has been removed. D T₂-weighted cervical axial MRI, the soft disc herniation has been removed.

(● Fig. 2D). Utmost care should be taken not to damage the nerve root, and to gently remove the herniated fragment with a fine blunt instrument. Free mobilization of the nerve root is essential, and at the end of the procedure, the neural foramen should be probed with a blind instrument. Venous bleeding from the neural foramina is usually observed after removal of the disc material. Bone-wax use is the choice for bone bleeding. The layers require anatomic closure. Thus, postoperatively, patients can be mobilized at the sixth hour after surgery, as were our patients.

Results

In 49 patients (58%) soft disc herniation was removed (● Fig. 3), while in 35 patients (42%) there were osteophytes. Successful relief of radiculopathy symptoms was achieved in 80 patients (96%). In 4 patients, symptoms recurred but no further surgical intervention was performed. One patient (1.2%) developed kyphosis. The only complication observed intraoperatively was root injury in one patient (1.2%). Mean hospitalization time was 48 hours.

Discussion

The posterior approach for cervical pathology was originally reported by Mixter and Barr, and the keyhole foraminotomy was subsequently popularized by Scoville, Epstein, and Fager, Ducker later coining the term “laminoforaminotomy” [6–8]. However, despite the lesser intraoperative and postoperative risks compared with anterior approaches, the laminoforaminotomy has lost ground when compared with anterior approaches for the management of lateral and foraminal cervical pathology.

Witzmann et al. reported their series with 67 surgically treated patients having compressive radiculopathy. They stated that posterior cervical foraminotomy is an efficient means of decompressing lateral spinal roots compromised by soft disk herniations or osteophytic spurs, without the risk of an anterior approach with or without fusion. Careful patient selection and microsurgical technique are essential in obtaining consistent and excellent results. Additionally, the recent trend toward minimally invasive techniques and keyhole operations in neurosurgery and other specializations favors the posterior approach [9]. Takayama et al. reported two cases of ossification and calcification of the cervical ligamentum flavum which underwent surgical treatment via a keyhole posterior approach. They stated that this method is useful in the treatment of cervical calcified ligamentum flavum [10].

Keyhole foraminotomy or “laminoforaminotomy” are the terms used to describe the typical posterior approaches for resecting lateral or foraminal cervical disc herniations or spurs [5, 7, 11–13]. They may be performed unilaterally at one or more levels and bilaterally, at one or more levels (fenestration approach), or in combination with a laminectomy or laminoplasty.

Anterior versus posterior surgical management of lateral and foraminal cervical disc disease remains controversial. The keyhole foraminotomy or laminoforaminotomy allows dorsal resection without the instability encountered with anterior cervical approaches, with more limited morbidity. Unilateral radiculopathy can be addressed with the laminoforaminotomy, while

bilateral or multifocal radiculopathy with myelopathy may additionally require a laminectomy or laminoplasty [14].

The soft tissue or calcified composition and extent of foraminal pathology dictate how much cephalad and caudad laminae have to be removed. For most foraminal lesions, more cephalad rather than caudad laminae have to be removed. Ebraheim et al. noted that a semicircular laminotomy involving cephalad lamina may be all that is needed for a lateral soft disc intrusion since the disc space itself is located above the leading edge of the caudad lamina [15]. However, for lesions with greater cephalad and caudad extension, more extensive laminotomy or complete hemilaminectomy may be required.

Bilateral foraminal disease at a single level can be managed by the fenestration procedure that includes bilateral laminoforaminotomies separated by the preserved spinous processes, interspinous and supraspinous ligaments [8].

After the nerve root has been exposed, it is vital to discern whether the dorsal sensory and ventral motor roots are combined in a single dural sleeve, or if the ventral motor root has a separate, thinner, dusky dural investment. This identification is critical to avoid confusing a tethered ventral motor root surrounded by perineural adhesions with the disc herniation itself. Typically, a compressed nerve root is surrounded by an engorged epidural venous plexus that must be coagulated, where feasible, with a bipolar forceps [14]. A major benefit of the dorsal approach is the ability to expose parts of virtually the entire root as needed, although more extensive facetectomy may warrant fusion.

Laminectomy with laminoforaminotomy may be required in patients with diffuse single or multilevel stenosis, accompanied by lateral and foraminal disease. Laminoplasty can also be combined with foraminotomy for decompression of myelopathy in addition to significant focal radiculopathy [2, 3, 5].

The extent of facet resection required during laminoforaminotomy is typically 25% and rarely exceeds 50% [9, 11, 16]. Chen et al. found that the laminoforaminotomy was “less destabilizing” to the cervical spine than the anterior discectomy performed with or without fusion [11]. Ugur et al. found that there is no space between pedicle and cervical dura and superior root [17]. In our cases, the medial border of the pedicle was drilled in order to reduce retraction on the dural sac and nerve root. It should be kept in mind that most of the neurological deficits develop with excessive retraction of the cervical dural sac and nerve root during exploration of the herniated disc.

A 2.2% or greater intraoperative complication rate may be observed in patients undergoing laminoforaminotomy. Complications may include excessive blood loss in obese patients having surgery in the prone position. Alternatively, “relative hypotension” may occur in patients operated on in the sitting position, resulting in cord or brain ischemia. Cerebrospinal fluid fistula, increased epidural bleeding, pneumocephalus, vertebral artery injury, cord and root injuries are the other possible complications of this surgery [2–5].

This technique also may prevent damage to the intradural variant of the cervical nerve root fibers which were described by Pernecky and Sunder-Plassmann before [18]. Fessler et al. explained that minimally invasive cervical foraminotomy continues to be their procedure of choice for properly selected patients with cervical radiculopathy [19, 20].

In conclusion; magnetic resonance imaging and computed tomographic studies combined should allow the surgeon to judiciously select patients for a laminoforaminotomy approach or

“keyhole approach”. In these selected patients, the surgical results are excellent with minimal morbidity.

References

- 1 Smith GW, Robinson RA. The treatment of certain cervical-spine disorders by anterior removal of intervertebral disc and interbody fusion. *J Bone Joint Surg [Am]* 1958; 40: 607–624
- 2 Yasargil MG. Cervical Disc Herniation. In: Yasargil MG (ed). *Microsurgery Applied to Neurosurgery*. Georg Thieme Verlag, Stuttgart, 1969, pp 177–179
- 3 McCulloch JA, Young PH. Posterior microlaminotomy-facetotomy for foraminal soft discs and spurs. In: McCulloch JA, Young PH (eds). *Essentials of Spinal Microsurgery*. Lippincott-Raven Publishers, 1998, pp 187–194
- 4 Aldrich F. Posterolateral microdiscectomy for cervical monoradiculopathy caused by posterolateral soft cervical disc sequestration. *J Neurosurg* 1990; 72: 370–377
- 5 Ball AP. Management of cervical disc disease: Posterior Approach. In: Menezes AH, Sonntag VKH (eds). *Mc Graw-Hill*, 1996, pp 539–546
- 6 Zeidman SM, Ducker TB. Posterior cervical laminoforaminotomy for radiculopathy: review of 172 cases. *Neurosurgery* 1993; 33: 356–362
- 7 Epstein JA, Lavine LS, Aronson HA, Epstein BS. Cervical spondylotic radiculopathy: the syndrome of foraminal constriction treated by foraminotomy and the removal of osteophytes. *Clin Orthop Relat Res* 1965; 40: 113–122
- 8 Scoville WB. Cervical disc classifications, indication and approaches with special reference to posterior keyhole operation. In: Dunsker (ed). *Cervical spondylosis*. New York, Raven Press, 1981, pp 155–167
- 9 Witzmann A, Hejazi N, Krasznai L. Posterior cervical foraminotomy. A follow-up study of 67 surgically treated patients with compressive radiculopathy. *Neurosurg Rev* 2000; 23: 213–217
- 10 Takayama S, Kuribayashi K, Miyamoto Y, Nakasu Y, Handa J. Ossification and calcification of the cervical ligamentum flavum case reports. *No To Shinkei* 1993; 45: 859–563
- 11 Chen BH, Natarajan RN, An HS, Anderson GB. Comparison of biomechanical response to surgical procedures used for cervical radiculopathy: posterior keyhole foraminotomy versus anterior foraminotomy and discectomy versus anterior discectomy with fusion. *J Spinal Disord* 2001; 14: 17–20
- 12 Fager CA. Posterolateral approach to the ruptured median and paramedian cervical disc. *Surg Neurol* 1983; 20: 443–452
- 13 Henderson CM, Hennessey RG, Shuey HM, Shackelford EG. Posterolateral foraminotomy as an exclusive operative technique for cervical radiculopathy: a review of 846 consecutive operated cases. *Neurosurgery* 1983; 13: 504–512
- 14 Epstein NE. A review of laminoforaminotomy for the management of lateral and foraminal cervical herniations and spurs. *Surg Neurol* 2002; 57: 226–234
- 15 Ebraheim NA, Xu R, Bhatti RA, Yeasting RA. The projection of the cervical disc and uncinat process on the posterior aspect of the cervical spine. *Surg Neurol* 1999; 51: 363–367
- 16 Raynor RB, Pugh J, Shapiro I. Cervical facetectomy and its effect on spine strength. *J Neurosurg* 1985; 63: 278–282
- 17 Ugur HC, Attar A, Uz A, Egemen N, Caglar YS, Genc Y. Surgical anatomic evaluation of the cervical pedicle and adjacent neural structures. *Neurosurgery* 2000; 47: 1162–1168; discussion 1168–1169
- 18 Perneczky A, Sunder-Plassmann M. Intradural variant of cervical nerve root fibres. Potential cause of misinterpreting the segmental location of cervical disc prolapses from clinical evidence. *Acta Neurochir (Wien)* 1980; 52: 79–83
- 19 Fessler RG, Khoo LT. Minimally invasive cervical microendoscopic foraminotomy: an initial clinical experience. *Neurosurgery* 2002; 51 (Suppl 5): S37–45
- 20 Lam S, Khoo LT, Cannestra A, Holly L, Shamie AN, Wang J, Fessler RG. A long-term clinical outcome analysis of minimally invasive cervical foraminotomy for the treatment of cervical radiculopathy. *Eur Spine J* 2005; 14 (Suppl 1): S2