

# Unusually Fatal Complication of Large Sacral Chordoma: A Case Report

## Dev Sakral Kordomanın Nadir Ölümcül Komplikasyonu: Bir Olgu Sunumu

### ABSTRACT

Sacral chordomas are known as slow-growing, locally aggressive tumors. The management strategy and surgical treatment options are well discussed in literature. However, few reports mention the complications of sacral chordoma. We present a case with an unexpected large sacral chordoma developing within sixth months and causing disseminated intravascular coagulation and severe cachexia. These complications limited the surgical intervention and had a fatal result due to the hemorrhagic diathesis.

**KEY WORDS:** Chordoma, fatal, sacrum.

### ÖZ

Sakral kordomalar yavaş büyüyen lokal agresif tümörler olarak bilinmektedir. Literatürde yaklaşım stratejileri ve cerrahi yaklaşımlar tartışılmıştır. Ancak sakral kordomanın komplikasyonları ile ilgili çok az vaka bildirilmiştir. Olgumuzda, altı ay içinde geniş hacimli boyutlara ulaşan ve tümör nedenli yaygın damar içi pıhtılaşma hastalığı ile ciddi kaşeksiye neden olan bir sakral kordoma olgusunu sunduk. Bu komplikasyonlar cerrahi yaklaşımı engelledi ve hemorajik diatezi ile ölümcül yatkinlığa neden oldu.

**ANAHTAR SÖZCÜKLER:** Kordoma, ölümcül, sakrum.

Efkan ÇOLPAN<sup>1</sup>  
Şükrü ÇAĞLAR<sup>2</sup>  
Gökmen KAHILOĞULLARI<sup>2</sup>  
Selim EREKUL<sup>2</sup>  
Zeki ŞEKERCI<sup>1</sup>

1 Department of Neurosurgery,  
SSK Ankara Education and Research  
Hospital, Dışkapı, Ankara, Turkey.

2 Department of Neurosurgery,  
School of Medicine, Ankara University,  
06100 Sıhhiye, Ankara, Turkey

Received : 11.08.2003

Accepted : 03.05.2004

Correspondence address

**Şükrü ÇAĞLAR**

Ankara Üniversitesi Tıp Fakültesi

Nöroşirürji Anabilim Dalı

06100 Sıhhiye, Ankara, Turkey

Phone : +90 312 3103333/2300.

e-mail : sukrucaclar@yahoo.com

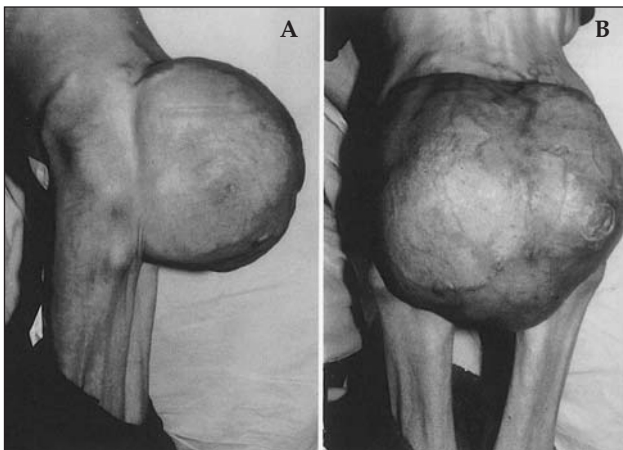
**INTRODUCTION**

Chordomas develop from remnants of notochord (3, 11, 19). This relatively rare tumor is predominantly located in the sacro-coccygeal region and often shows slow progression (3, 11, 19). The complex anatomical structure of the sacro-coccygeal region makes the radiological diagnosis of the tumor more difficult (4, 6, 19). Magnetic Resonance Imaging and Computed Tomography have increased the tumor diagnosis rate in the sacro-coccygeal region. Early diagnosis of the tumor can make its management easier (1, 3, 8, 10, 13, 18, 19).

Sacral chordomas are classified in the group of locally aggressive slow-growing tumors (8, 18, 19). However, we report a case of sacral chordoma with an aggressive clinical course. The tumor grew to an unexpected size within six months and caused a fatal hemorrhagic diathesis. This unusually large sacral chordoma case is presented and the complications of sacral chordoma are discussed.

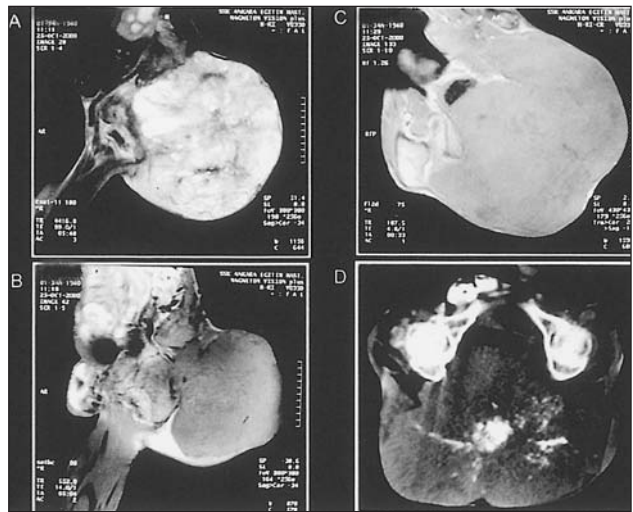
**CASE REPORT**

A 61-year-old male presented with a large sacral mass. The patient reported remarkable increase in the size and marked weight loss in the last two months. Physical examination revealed severe cachexia and an ulcerated 40 cm x 25 cm sacro-coccygeal mass (Figure 1A,B). Neurological evaluation demonstrated anal sphincter dysfunction, urinary incontinence, loss of the cremasteric reflex and hypoesthesia over the sacral dermatome. Magnetic resonance imaging showed a large exophytic sacral mass (Figure 2). Percutaneous

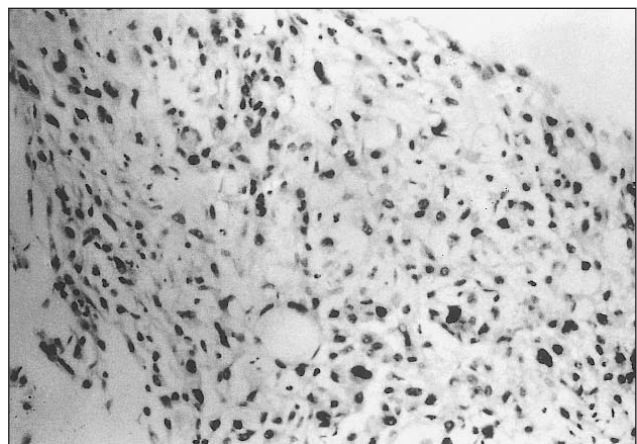


**Figure 1:** Lateral (A) and posterior (B) view of the patient showing severe cachexia and huge ulcerated sacral mass

needle biopsy was performed and the specimens were diagnosed as chordoma (Figure 3). The patient's condition and severe anemia precluded surgical intervention. He was transferred to the Hematology Department for the treatment of anemia and nutritional support. The acute hemorrhagic diathesis and laboratory results suggested disseminated intravascular coagulation (DIC). Other possible causes for DIC were investigated but no other pathology was detected. The patient died because of severe progressive DIC on the sixth day following admission.



**Figure 2:** Sagittal T1-weighted MRI image (A) and Sagittal T2-weighted MRI image (B) demonstrating exophytic tumor and pelvic extension of tumor, C) Axial MRI image showing huge mass infiltration in the sacrum, D) Axial Computerized Tomography scan showing central calcification into the huge mass.



**Figure 3:** Photomicrograph showing large colorless cytoplasm of tumor cells and moderate nucleolus. Hypercellularity and characteristic mesenchymal cells suggest the diagnosis of chordoma. H&E X 100.

## DISCUSSION

Sacral chordomas are known as slow-growing, locally aggressive tumors (8, 19). Their median survival and recurrence rate has been reported as 6-7 years and 45-81.8% respectively (18, 19). York et al have reported an 8 months of disease-free interval following subtotal resection compared with 2.27 years following radical surgery (19). Extensive surgery such as total sacrectomy has decreased the recurrence rate and increased the length of the disease-free interval but with increased morbidity (7, 14, 17-19).

Many reports have discussed total sacrectomy (1, 3, 7-9, 14, 17-19). This extensive surgical procedure may have an increased risk of surgical complications. Most authors believe that a multidisciplinary surgical team perform the procedure (8, 15, 17-19). This multidisciplinary team must consist of the orthopedic surgeon, neurosurgeon, and general surgeon to perform different stages of this long operation.

Sacral chordomas usually grow with anterior extensions that augment pelvic organ infiltration by the tumor (4, 6). In case of pelvic organ infiltration with tumor tissue, some pelvic organ resection may be necessary for surgical cure (3, 17-19). Surgery on the pelvic organs may have an influence on mortality, morbidity, and quality of life. In our case, the large mass extended posteriorly like a giant mushroom and this very unusual for a sacral chordoma.

We had not previously observed such a large sacral chordoma and we searched the current medical literature for its management. We found only a few case reports of large or huge sacral chordomas with reported surgical experience (4, 5, 7, 14-16). Our patient showed an unexpected clinical course with severe progressive disseminated intravascular coagulation disorder. We did not find any reports of a hematological disorder with sacral chordoma. Interestingly, Carson and Streib reported a case of clivus chordoma with myasthenia gravis (2). It was associated with cross-immunological reaction against the chordoma tissue. Papadimitriou et al reported a case of sacral chordoma associated with nephrotic syndrome and proposed that antibodies against chordoma cells produced the disease (12).

The case showed unusual posterior extension and caused death by DIC. We emphasize that large sacral chordomas may lead to tumor related metabolic and/or hematological complications. This unique case is a reminder that possible hematological complications of sacral chordomas may limit surgical intervention.

## REFERENCES

- Blatter G, Halter Ward EG, Ruffin G, Jeanneret B: The problem of stabilization after sacrectomy. *Arch Orthop Trauma Surg* 114; 40-42, 1994
- Carson HJ, Streib EW: Myasthenia gravis in a man with a history of chordoma: observations of muscle-like antigens in carcinoma. *Hum Pathol* 24; 339-342, 1993
- Chandawarkar RY: Sacrococcygeal chordoma: review of 50 consecutive patients. *World J Surg* 20; 717-719, 1996
- Coombs RJ, Coiner L: Sacral chordoma with unusual posterior radiographic presentation. *Skeletal Radiol* 25; 679-681, 1996
- Gray SW, Singhabhandhu B, Smith RA, Skandalakis JE: Sacrococcygeal chordoma: Report of a case and review of the literature. *Surgery* 78; 573-582, 1975
- Hudson TM, Galceran M: Radiology of sacrococcygeal chordoma. Difficulties in detecting soft tissue extension. *Clin Orthop*; 237-242, 1983
- Ishii K, Chiba K, Watanabe M, Yabe H, Fujimura Y, Toyama Y: Local recurrence after S2-3 sacrectomy in sacral chordoma. Report of four cases. *J Neurosurg* 97; 98-101, 2002
- Jeanrot C, Vinh TS, Anract P, De Pinieux G, Ouaknine M, Forest M, Tomeno B: [Sacral chordoma: retrospective review of 11 surgically treated cases]. *Rev Chir Orthop Reparatrice Appar Mot* 86; 684-693, 2000
- Karakousis CP: Sacral resection with preservation of continence. *Surg Gynecol Obstet* 163; 270-273, 1986
- Klekamp J, Samii M: Spinal chordomas--results of treatment over a 17-year period. *Acta Neurochir* 138; 514-519, 1996
- Logroscino CA, Astolfi S, Sacchettoni G: Chordoma: long-term evaluation of 15 cases treated surgically. *Chir Organi Mov* 83; 87-103, 1998
- Papadimitriou K, Nakopoulou L, Billalis D, Papacharalampous XN: [A chordoma of sacrococcygeal region as a cause of nephrotic syndrome (author's transl)]. *Zentralbl Allg Pathol* 120; 500-504, 1976
- Prabhakaran PS, Misra S, Kannan V, Chandrashekar M, Vijayakumar M, Veerendrakumar KV, Anantha N: Sacral chordomas: a 10-year study. *Australas Radiol* 42; 42-46, 1998
- Tomita K, Tsuchiya H: Total sacrectomy and reconstruction for huge sacral tumors. *Spine* 15; 1223-1227, 1990
- Vara Lopez R: [Giant sacro-coccygeal chordoma and function of the anal and bladder sphinctern]. *An R Acad Nac Med* 93; 509-527, 1976
- Worthy TS: Sacrococcygeal chordoma--two cases with unusual features. *Clin Radiol* 16; 412-413, 1965
- Wuisman P, Lieshout O, Sugihara S, van Dijk M: Total sacrectomy and reconstruction: oncologic and functional outcome. *Clin Orthop*; 192-203, 2000
- Yonemoto T, Tatezaki S, Takenouchi T, Ishii T, Satoh T, Moriya H: The surgical management of sacrococcygeal chordoma. *Cancer* 85; 878-883, 1999
- York JE, Kaczaraj A, Abi-Said D, Fuller GN, Skibber JM, Janjan NA, Gokaslan ZL: Sacral chordoma: 40-year experience at a major cancer center. *Neurosurgery* 44; 74-79; discussion 79-80, 1999